

Arthroscopic Treatment of Traumatic Hip Dislocation

John P. Begly, MD
Bryan Robins, BS
Thomas Youm, MD

Abstract

Traumatic hip dislocations are high-energy injuries that often result in considerable morbidity. Although appropriate management improves outcomes, associated hip pathology may complicate the recovery and lead to future disability and pain. Historically, open reduction has been the standard of care for treating hip dislocations that require surgical intervention. The use of hip arthroscopy to treat the sequelae and symptoms resulting from traumatic hip dislocations recently has increased, however. When used appropriately, hip arthroscopy is a safe, effective, and minimally invasive treatment option for intra-articular pathology secondary to traumatic hip dislocation.

Because the hip is an inherently stable joint, substantial force is necessary to dislocate it. With appropriate management, potential complications and disability can be minimized. However, hip dislocations are severe injuries that often lead to future morbidity. Traumatic hip dislocation often is complicated by intra-articular and periarticular pathology in the soft tissues and bone. If not effectively managed, these sequelae may contribute to considerable future morbidity. The increased use of MRI in the management of hip dislocation has led to an increase in the diagnosis of associated pathology. Hip arthroscopy is a safe and effective modality for management of the acute and chronic sequelae of traumatic hip dislocation.¹⁻³

and identify any associated fractures (Figure 2). Recently, the use of MRI and magnetic resonance angiography (MRA) in the workup of hip dislocations has become more common. In addition to identifying the associated injuries mentioned earlier, MRI and MRA are effective in pinpointing common concomitant injuries, such as loose articular bodies, posterior wall impaction, chondral lesions, and osteonecrosis (Figure 3). MRI provides detailed resolution of the bone, cartilage, and surrounding soft-tissue structures and is the preferred imaging modality for the examination of intra-articular structures.¹ MRI and MRA often delineate previously unrecognized intra-articular pathology. In some cases, this pathology might be appropriately treated arthroscopically rather than with a classic open technique, which potentially can be associated with greater morbidity.

Imaging

Standard radiographic assessment of a traumatic hip dislocation includes an AP view of the pelvis (Figure 1). Postreduction CT also should be obtained to evaluate the reduction, assess for the presence of loose bodies,

Open Versus Arthroscopic Treatment

Although complications are rare, hip arthroscopy does carry the risk of

From the Department of Orthopaedics, New York University Hospital for Joint Diseases, New York, NY (Dr. Begly and Dr. Youm), and the University of Maryland School of Medicine, College Park, MD (Mr. Robins).

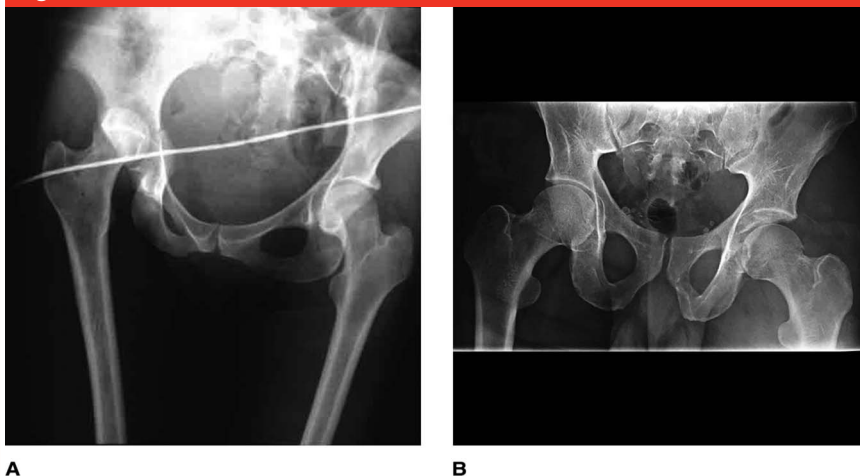
Dr. Youm or an immediate family member is a member of a speakers' bureau or has made paid presentations on behalf of and serves as a paid consultant to Arthrex and Smith & Nephew. Neither of the following authors nor any immediate family member has received anything of value from or has stock or stock options held in a commercial company or institution related directly or indirectly to the subject of this article: Dr. Begly and Mr. Robins.

J Am Acad Orthop Surg 2016;24:309-317

<http://dx.doi.org/10.5435/JAAOS-D-15-00088>

Copyright 2016 by the American Academy of Orthopaedic Surgeons.

Figure 1

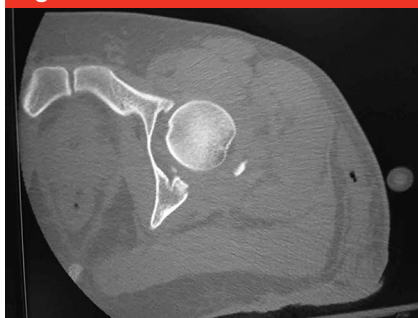

A

B

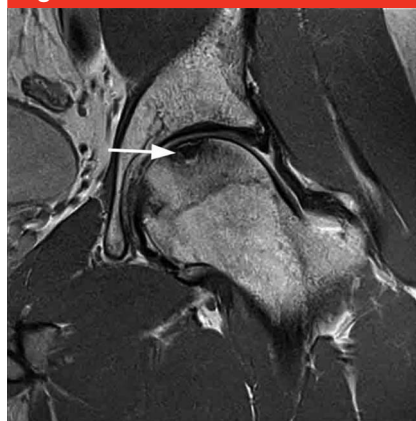
AP radiographs of the pelvis demonstrating a traumatic hip dislocation (A) and a traumatic hip fracture-dislocation (B).

Figure 2



Axial CT of the left hip demonstrating a traumatic left fracture-dislocation with a comminuted, displaced left posterior wall fracture and loose intra-articular fracture fragments.

Figure 3



Coronal T1-weighted magnetic resonance image of the femoral head demonstrating osteonecrosis (arrow).

several unique complications that must be considered before undertaking arthroscopic intervention. Overall complication rates range from 0.5% to 7%.^{1,4,5} Most complications are the result of transient neuroparaxia. In a systematic review of the complications of hip arthroscopy, Harris et al⁵ reviewed 92 studies with >6,000 patients and reported a major complication rate of 0.58% and a revision rate of 6.3% that directly correlated with surgeon experience.

Compared with open procedures, hip arthroscopy is associated with less morbidity. Open arthrotomy is associated with higher rates of complications, including infection, stiffness, venous thromboembolism (VTE), and neurovascular compromise.^{2,6} Compromise of the vascular supply to the femoral head is a particular risk associated with arthrotomy.³ In a study of complications in patients undergoing open arthrotomy, Ganz

et al⁷ reported a 37% incidence of postoperative heterotopic ossification (HO) as well as cases of overlying cosmetic deformity and rupture of the ligamentum teres. Similarly, Swiontkowski et al⁸ reported a 24% overall incidence of HO and a 17% incidence of osteonecrosis in a study of 24 hips treated with open arthrotomy. Although technically demanding, arthroscopic treatment offers several advantages over arthrotomy, including less disruption of the natural hip anatomy, less blood loss, a shorter recovery time, improved cosmesis, and a lower risk of neurovascular compromise.^{4,9,10}

Complications

The incidence of HO after hip arthroscopy ranges from 1.0% to 6.3%.¹¹ Bedi et al¹² reported a 4.7% incidence of radiographically evident HO after hip arthroscopy, and the rates of HO in patients treated with and without indomethacin prophylaxis were 1.8% and 8.3%, respectively. In all cases, thorough irrigation of the joint at the conclusion of the procedure is recommended. The clinical decision to administer medical prophylaxis can be made based on the clinical scenario and surgeon preference.

Given the proximity of vascular structures to the surgical field as well as the use of traction, VTE is a potential complication of hip arthroscopy. The exact incidence of VTE after hip arthroscopy remains unclear; however, in a recent study of 139 patients who underwent hip arthroscopy, Davidovitch et al¹³ reported a VTE rate of 1.4%. Because of this low incidence, many surgeons do not routinely use deep vein thrombosis prophylaxis in patients without risk factors. This decision varies according to the postoperative protocol, institutional guidelines, and surgeon preference, however.

Neurovascular complications associated with arthroscopy can occur secondary to distraction or compression. Distraction-related nerve palsy is associated with prolonged procedure times and excessive traction force. The most commonly reported continuous traction time limit is 2 hours; however, some authors recommend a maximum time of 60 minutes, if possible.¹ Intermittent traction should be used in complex, lengthy procedures. Although no consensus exists regarding a maximal force threshold, limits of 50 to 70 lb of traction are recommended.¹ Distraction nerve palsy most commonly affects the sciatic and femoral nerves and is usually transient. Compression-related palsy arising from the incorrect placement and use of the perineal post typically affects the pudendal nerve. The perineal post also may contribute to skin damage, pressure necrosis, and hematoma formation if incorrectly used. The use of posts with a diameter >9 cm is recommended to distribute forces effectively and safely. Neurovascular injury associated with portal placement is rare. In a systematic review of >6,000 patients, Harris et al⁵ reported that 1.4% of patients had a neurovascular injury. Of all nerve deficits, 99% were temporary. The pudendal nerve was the most frequently affected (40%) followed by the lateral femoral cutaneous nerve (21%).

Iatrogenic injuries associated with arthroscopy include damage to the chondral surfaces and iatrogenic labral injury. Chondral pathology disrupts the articular surface and increases the risk of future joint degeneration. Excessive labral resection and aggressive acetabuloplasty or capsulotomy may lead to iatrogenic instability. Adequate distraction of the hip joint and appropriate visualization are necessary to safely perform these procedures. Iatrogenic insult can be minimized with meticulous technique. The arthroscopic

techniques we describe here should be performed only by surgeons experienced in hip arthroscopy.

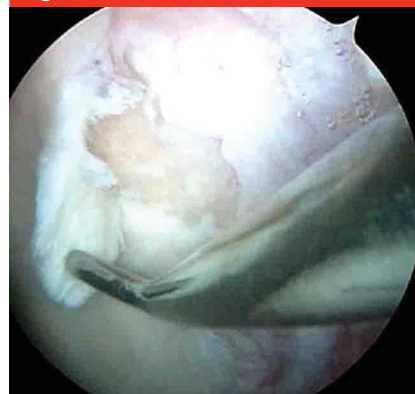Fluid extravasation is the most dangerous complication associated with traumatic hip dislocation. This complication is particularly important to consider in the setting of acute or chronic trauma. Incongruities of the surrounding bony and soft-tissue structures of the hip increase the risk of fluid extravasation, which can contribute to compressive nerve palsy. In addition, extravasation into the abdomen and retroperitoneum may lead to multisystem dysfunction and severe pathophysiologic responses, such as abdominal compartment syndrome, respiratory failure, and cardiac arrest. Bartlett et al¹⁴ reported on a case of cardiac arrest caused by fluid extravasation during hip arthroscopy in a patient with a bicolunar acetabular fracture.¹⁴ When fluid extravasation occurs, the procedure should be aborted, and a general surgery consultation should be obtained. Fluid extravasation can be prevented with careful monitoring of the fluid balance and by limiting the length of the procedure. Management of this complication includes administration of diuretics, possible paracentesis, maintenance of the patient's core body temperature, and frequent clinical and physiologic monitoring. Because of the potentially devastating morbidity of fluid extravasation, arthroscopic techniques should not be performed until the risk of this complication is eliminated.

Arthroscopic Intervention

Diagnosis

In the setting of hip dislocation, hip arthroscopy is a valuable diagnostic tool that can be used to detect acute chondral damage that may complicate traumatic hip dislocation, which is a risk factor for the development of

Figure 4

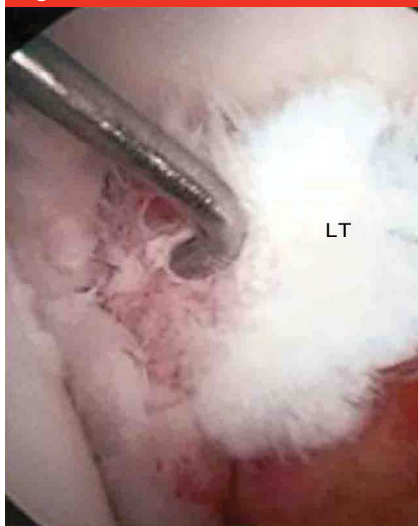


Arthroscopic image of the hip demonstrating a chondral injury identified during arthroscopy.

arthritic changes (Figure 4). Epstein et al¹⁵ believed that the rates of chondral injury after hip fracture-dislocation were so high that it was appropriate to offer hip arthrotomy to all patients with such traumatic injuries. Philippon et al¹⁶ reported on the arthroscopic findings of 14 elite athletes who sustained traumatic hip dislocation; all of the athletes had chondral lesions. Ilizaliturri et al¹⁷ examined 17 cases of posterior hip dislocation and found that all hips had evidence of femoral chondral damage identified arthroscopically. All but one case also displayed evidence of acetabular chondral pathology. Over time, chondral lesions may lead to the development of osteochondritis dissecans and loose intra-articular fragments, which produce pain and represent a risk factor for accelerated joint degeneration.¹⁸ Early identification of these injuries can facilitate effective treatment to prevent future joint degeneration.

During hip dislocation, traumatic contact between the femoral neck and the acetabulum may result in capsular disruption and shearing of the ligamentum teres and/or capsule on the acetabular lip¹⁹ (Figure 5). Although injuries to the ligamentum

Figure 5



Arthroscopic image demonstrating a rupture of the ligamentum teres (LT).

teres are rare overall, Philippon et al¹⁶ reported incidence rates as high as 79% in hips after traumatic dislocation. In the study by Ilizaliturri et al,¹⁷ all patients showed evidence of injury to the ligamentum teres. Several studies have noted the presence of capsular redundancy after dislocation, although the prevalence of this complication has not been reported.¹ The definitive clinical repercussions of rupture of the ligamentum teres remain unknown; however, if left untreated, this injury may lead to recurrent joint pain and instability.² The development of degenerative arthritis associated with complete rupture of the ligamentum teres has been suggested.²⁰

Despite the lack of long-term and large comparative studies, some authors have proposed the use of hip arthroscopy to treat chondral damage and injuries to the ligamentum teres. Generally, arthroscopic treatment consists of identifying unstable chondral lesions and then debriding and stabilizing them. Microfracture of exposed subchondral bone may be performed in appropriate clinical settings.¹⁷ Matsuda and Safran¹⁸

reported on the arthroscopic treatment of osteochondral dissecans of the femoral head. The lesion was treated with arthroscopic drilling and the placement of two headless metallic compression screws for fixation. The authors observed that arthroscopy is valuable for the staging of chondral lesions, the resection of free fragments, and concurrent treatment of associated pathology.

Good preliminary outcomes have been reported with arthroscopic treatment of injuries to the ligamentum teres.² In a recent systematic review of 87 patients with these injuries, de SA et al²¹ reported success with both arthroscopic débridement and reconstruction. Overall, a 40% improvement in postoperative functional scores was observed, and 89% of patients returned to their preoperative activity level. The authors concluded that arthroscopic débridement, along with reconstruction (when possible), is an effective method of treating injuries of the ligamentum teres.

Acute Injuries

The most important aspect of managing traumatic hip dislocation is the efficient and successful reduction of the hip because the time to reduction correlates with the risk of osteonecrosis.^{22,23} Hip arthroscopy does not have a proven role in the reduction of an acute dislocation. Dislocations that cannot be managed with closed reduction should be treated with open reduction.

Traumatic hip dislocation often is complicated by concomitant bony pathology, which may be acute or develop over time. Historically, when surgical intervention was indicated, open procedures were the standard of care. Many of these associated injuries can be treated safely and effectively with hip arthroscopy, however. In a prospective analysis of hip arthroscopy outcomes, Byrd and

Jones³ found that the largest improvement in function was seen in patients whose pain was related to trauma, although the details of the trauma were not specified.³ Although treatment-specific long-term outcome studies currently are lacking, we believe that hip arthroscopy is a promising method of treating the complications of traumatic hip dislocation.

Fractures of the acetabulum and femur are associated with traumatic hip dislocation. Although fractures of the femoral head associated with traumatic hip dislocation are relatively rare, Epstein et al¹⁵ reported that the incidence ranges from 6% to 15%. These fractures occur secondary to shearing forces acting on the femoral head as it engages with the acetabular wall during dislocation. The resultant fragment often is displaced into the joint, and concomitant injury to the ligamentum teres may be present. These fractures can compromise the alignment and biomechanics of the articular surfaces and, if not addressed, they pose a risk of future joint dysfunction and pain. Epstein et al¹⁵ reported that arthritis develops in >50% of patients with a hip dislocation and femoral head fracture.

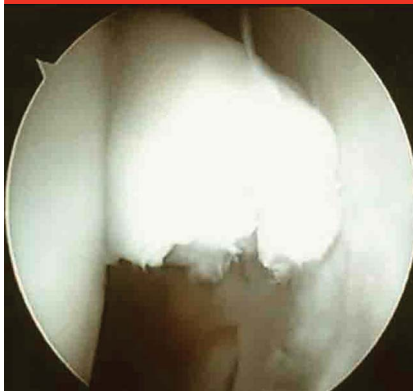Although large, complex fractures require open reduction and internal fixation, the use of hip arthroscopy as a treatment for smaller, subtler fractures,⁶ such as appropriate Pipkin femoral head fractures, has been proposed.^{18,24,25} Pipkin type I fractures often involve small fragments that are amenable to excision. Management of this fracture type includes simple shaving, removal of fragments via a grasper, and manipulation of fragments into position with threaded Steinmann pins so that they can be removed by a burr and/or shaver.¹ For larger fragments, fixation may be appropriate. Park et al⁶ managed these fragments with reduction,

provisional fixation with Kirschner wires, and definitive fixation with a 3.5-mm cortical screw. In an earlier study, Park et al²⁴ described the arthroscopic management of a Pipkin type IV fracture (ie, femoral head fracture with posterior acetabular wall fracture) by removing free fragments and repairing the associated labral tear with suture anchors.

Hip arthroscopy also has been used to directly observe the reduction and percutaneous pinning of fractures in the weight-bearing region of the acetabulum.²⁶ To our knowledge, long-term outcomes data on the arthroscopic management of fractures associated with traumatic hip dislocation have yet to be published. The reports referenced earlier represent level IV and level V evidence, and although the techniques described were successful, they were not compared with alternative treatment methods; therefore, whether arthroscopic fixation provides any advantage over fixation through an open approach remains unknown. With continued use and expanding indications, the application of hip arthroscopy for management of complex traumatic hip dislocations should be expected to increase.

Loose intra-articular bodies associated with traumatic hip dislocation are common (Figure 6). In a study of 29 posttraumatic hips, Khanna et al²⁷ noted a 59% incidence of loose intra-articular bodies. In a retrospective study of 36 hips treated with arthroscopy to remove loose bodies after a traumatic injury, Mullis and Dahners²⁸ reported that the incidence of loose intra-articular fragments after fracture-dislocation episodes and/or posterior wall fractures was 92%. All simple dislocations were found to have loose bodies on arthroscopy. Concentric reduction and negative radiography and CT do not guarantee that a joint will be free of loose fragments.^{1,16} Several studies have reported the presence of intra-

Figure 6

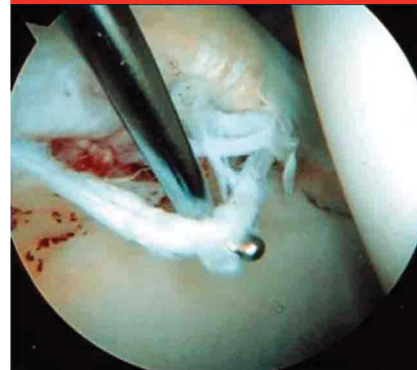


Arthroscopic image of the hip demonstrating an intra-articular loose body identified during arthroscopy.

articular loose bodies at rates of up to 78%, despite negative results on radiography and CT.^{26,28,29}

The presence of loose bodies within the hip joint may be the best indication for arthroscopic treatment after hip dislocation. Several authors have suggested a correlation between untreated loose fragments and the development of arthritis in a joint.^{1,2,9,15,17,28} This hypothesis has been confirmed in an animal model; suspensions of fragmented articular cartilage were injected into the joints of rabbits, and the subsequent development of arthritis was observed.³⁰ Because of the risk of third-body wear, loose intra-articular fragments present the clearest indication for arthroscopic treatment, and this has led some authors to offer arthroscopy to all patients who have sustained a hip dislocation.²⁸ Even before hip arthroscopy gained popularity, Epstein et al¹⁵ suggested that the presence of intra-articular loose bodies was an indication for arthrotomy. If surgery is planned, it should take place within 72 hours of dislocation to limit secondary chondral insult.⁴ It is important to fully evaluate the risks of arthroscopy in the acute period because injuries, such as

Figure 7



Arthroscopic image demonstrating a labral tear identified during hip arthroscopy.

periarticular fractures, may increase the risk of complications (eg, fluid extravasation). Manual and power arthroscopic instrumentation can be used to break loose bodies into a manageable size for removal.^{2,9,31} Although large-scale outcome studies are lacking, Byrd and Jones³ and Ilizaliturri et al¹⁷ reported improvement in functional outcome scores in patients who underwent arthroscopic removal of loose bodies.^{3,17} Arthroscopy is a minimally invasive option for removal of intra-articular loose bodies that can reduce the risk of subsequent posttraumatic joint degeneration and dysfunction.^{9,16,31}

Traumatic labral tears are similar to loose bodies in that they often occur concurrent with traumatic hip dislocation (Figure 7). Ilizaliturri et al¹⁷ used arthroscopy to evaluate 17 cases of posterior hip dislocation and found anterior and posterior labral tears in 14 and 16 cases, respectively.¹⁷ In a study of traumatic hip dislocation in 14 professional athletes, Philippon et al¹⁶ used arthroscopy to identify traumatic labral tears in all of the patients. Khanna et al²⁷ examined the prevalence of intra-articular pathology after trauma to the hip and reported that 27 of 29 hips (93%) had a labral tear. The authors also found MRI and

Table 1**Incidence of Complicating Injuries and Intra-articular Pathology Arthroscopically Identified After Traumatic Hip Injury**

Study	Injury	No. of Patients	Intra-articular Pathology			
			Loose Bodies (%)	Labral Tears (%)	Chondral Lesions (%)	Ligamentum Injury (%)
Philippon et al ¹⁶	Traumatic hip dislocation	14	NR	100	100	100
Ilizaliturri et al ¹⁷	Traumatic posterior dislocation	17	82	94	100	100
Yamamoto et al ²⁶	Traumatic hip dislocation	10 (11 hips)	73	NR	100	NR
Khanna et al ²⁷	Traumatic hip injury	28 (29 hips)	59	93	49	NR
Mullis and Dahners ²⁸	Traumatic hip dislocation or wall fracture	36	92	NR	NR	NR

NR = not reported

MRA to be sensitive for the diagnosis of intra-articular pathology, with 91% of tears identified on MRI/MRA confirmed on arthroscopy.

If left untreated, labral tears are associated with an accelerated onset of arthritis.^{1,4} Arthroscopy is safe and effective for hip preservation in patients with labral tears secondary to traumatic injury, with the goals of reestablishing intra-articular anatomy and stability and preventing future joint degeneration. Management of labral tears is one of the most accepted indications for hip arthroscopy, and many techniques have been described based on the characteristics of these tears. After close inspection of the injured tissue, labral débridement is performed using a ligament chisel or similar tool to isolate the injured tissue from healthy tissue. A shaver is then used to complete the removal of the injured tissue.² When appropriate, traditional suture anchors and/or knotless anchors can be used for primary repair of labral tears.³²

Good results have been achieved with arthroscopic labral débridement and repair.¹⁷ Kelly et al² reviewed early results of >500 arthroscopic labral débridements that they performed over a 7-year period and reported good or excellent results in approximately 90%, although not all of these tears were associated with traumatic hip

dislocation. Byrd and Jones³ reported a considerable increase in the Harris hip score after arthroscopic labral débridement in patients with no baseline hip arthritis.³ In a separate study, the authors retrospectively examined 37 patients with primary arthroscopic labral repairs, reporting considerable improvement in the Harris hip score in 34 patients (92%), and good or excellent results in 92%.³³ The patients in these studies did not sustain traumatic hip dislocations, however, nor were they trauma patients specifically. Long-term studies focused distinctly on arthroscopic management of labral tears secondary to acute hip trauma are currently unavailable and remain a goal for future research.¹ The incidence of acute hip pathology secondary to traumatic hip dislocation in several of the studies described earlier is summarized in Table 1.

Chronic Injuries and Sequelae

Osteonecrosis is a feared chronic complication of hip dislocation, and patients should be educated regarding their risk of this condition during the evaluation and before any intervention. The vascular supply to the femoral head—particularly the medial femoral circumflex artery—is at risk of injury in traumatic dislocation.

Vascular compromise leads to intra-vascular coagulation and ischemic necrosis, resulting in chondral fracture, failure, and collapse and causing accelerated joint degeneration. High rates of osteonecrosis are associated with traumatic hip injury, and osteonecrosis complicates approximately 10% to 25% of hip dislocations.¹⁹ The severity of the injury and the time to reduction are associated with increased risks of osteonecrosis. Hougaard and Thomsen²² reported that osteonecrosis developed in 58% of hips reduced after 6 hours from the time of injury, whereas osteonecrosis developed in just 4.8% of hips reduced within 6 hours. Brav²³ examined osteonecrosis rates in 262 hips when reduction was performed within or later than 12 hours from the time of injury. In hips reduced within 12 hours, the rate of osteonecrosis was 22%, whereas the rate in hips reduced after 12 hours was 52%.

Because of the considerable risk of osteonecrosis after dislocation, some authors recommend obtaining an MRI 6 weeks after traumatic hip injury to assess for osteonecrosis.²⁹ Failure to identify and treat osteonecrosis ultimately leads to femoral head collapse and accelerated degeneration of the hip joint. Patients with early-stage osteonecrosis may be relatively asymptomatic; delayed presentation

and diagnosis limit treatment options and result in worse outcomes.

In a 2010 meta-analysis of 16 studies and 664 hips, Mont et al³⁴ examined the natural history of asymptomatic osteonecrosis and determined that 392 hips (59%) with osteonecrosis progressed to symptoms and/or collapse. The authors recommended surgical treatment of even asymptomatic precollapse osteonecrotic lesions, with specific exceptions. Core decompression reduces intraosseous pressure in the femoral head, which encourages vascular and endothelial tissue growth through the release of angiogenic activating substances.

Arthroscopic-assisted core decompression is a well-described treatment for precollapse osteonecrosis.³⁵ Advantages of the arthroscopic technique include direct visualization of the joint (allowing thorough assessment for concomitant pathology), increased accuracy with regard to the position of sites for decompression, and direct assurance that the articular cartilage has not been penetrated during drilling.^{2,35} Gupta et al³⁶ asserted that arthroscopic-assisted core decompression was valuable for characterizing femoral head changes and diagnosing and treating associated pathology. For arthroscopic fixation, biocomposite screws or calcium phosphate can be placed into the intraosseous decompression tract to provide additional subchondral support.³⁵ Gaudilla et al¹⁰ described a technique involving drill holes at the femoral head-neck junction and the injection of platelet-rich plasma. The authors emphasized that an arthroscopic approach resulted in muscular preservation, reduced recovery times, lower infection rates, and reduced postoperative pain compared with traditional open procedures. Arthroscopic decompression allows the direct visualization of lesions, which increases the accuracy of treatment. In addition, intra-articular structures, such as the labrum, may be assessed

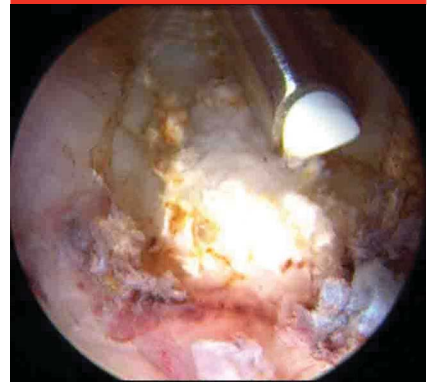
for damage and treated during the same procedure, thereby addressing other potential sources of pain and disability. Ellenrieder et al³⁷ reported an 86% success rate with arthroscopic-assisted core decompression for treatment of precollapse osteonecrosis, demonstrating that hip arthroscopy is an effective treatment method. Zhuo et al³⁸ recently compared arthroscopic-assisted core decompression with traditional decompression in patients with early-stage osteonecrosis. Patients treated arthroscopically had better pain relief, greater improvement in function, more complete lesion treatment, and better mitigation of disease progression than did those treated with traditional decompression.

HO is a chronic complication of hip dislocation. To our knowledge, the incidence of HO after hip dislocation remains unknown. Arthroscopy is an effective, minimally invasive technique for management of HO (Figure 8). Indications for surgery include symptomatic ectopic bone, limited range of motion, and concurrent hip pathology. Relative contraindications include immature or posterior heterotopic bone and Booker grade 4 lesions that demonstrate radiologic ankylosis. The senior author (T. Y.) has performed arthroscopic excision of HO in which ectopic bone is localized and removed with manual and power arthroscopic equipment, including burrs and graspers.¹¹ Patients in this study demonstrated considerable improvement in pain and function after excision. Large-scale outcome studies have yet to be published, however.

Postoperative Management

Compared with open surgical intervention, hip arthroscopy facilitates faster postoperative mobilization and accelerated rehabilitation. Postoperative rehabilitation protocols

Figure 8



Arthroscopic image demonstrating heterotopic ossification identified during hip arthroscopy.

vary, but protected weight bearing and postoperative bracing are commonly used, as is foot-flat weight bearing for 2 to 4 weeks after labral repair.^{1,2} Byrd and Jones³ recommended 4 weeks of partial weight bearing after labral repair and flexion to 90°, with neutral rotation maintained during the same period. For articular manipulation, patients typically are instructed to remain foot-flat weight bearing for 6 to 8 weeks.²

The senior author (T. Y.) has used the following protocols with success. After labral repair or cam resection, patients follow a protocol of 50% foot-flat weight bearing with crutches. After arthroscopic-assisted core decompression, a 4-week non-weight-bearing protocol with crutches is used. Patients resume weight bearing as tolerated immediately after an isolated HO resection. Weight bearing is advanced as appropriate at orthopaedic follow-up. In all cases, the patient wears an abduction brace for the first postoperative week, which allows flexion as tolerated but prevents extremes of rotation. Postoperative medication includes a 2-week course of NSAIDs for HO prophylaxis, a 1-week course of aspirin for deep vein thrombosis

prophylaxis, and a short course of antibiotics if an implant was used for repair.

Summary

Dislocation of the hip is a potentially devastating injury that is caused by a high-energy mechanism of injury. Dislocation must be managed effectively because delays in reduction and treatment lead to poor long-term outcomes. Although open techniques have been the standard of care for hip dislocations requiring surgical intervention, arthroscopy recently has been gaining popularity as a safe, effective, and minimally invasive method of treating acute and chronic pathology associated with traumatic dislocation. Compared with open techniques, arthroscopy is associated with less morbidity. Given the increased awareness of the potential benefits of appropriate arthroscopic treatment, we expect the use of hip arthroscopy for the treatment of traumatic hip dislocation to continue to increase.

References

Evidence-based Medicine: Levels of evidence are described in the table of contents. In this article, reference 34 is a level II study. References 12, 23, and 38 are level III studies. References 3, 5-8, 11, 13, 15-17, 21, 22, 25-29, 31, 33, and 37 are level IV studies. References 9, 10, 14, 18, 24, 35, and 36 are level V expert opinion.

References printed in **bold type** are those published within the past 5 years.

1. Lynch TS, Terry MA, Bedi A, Kelly BT: Hip arthroscopic surgery: Patient evaluation, current indications, and outcomes. *Am J Sports Med* 2013;41(5):1174-1189.
2. Kelly BT, Williams RJ III, Philippon MJ: Hip arthroscopy: Current indications, treatment options, and management issues. *Am J Sports Med* 2003;31(6):1020-1037.

3. Byrd JW, Jones KS: Prospective analysis of hip arthroscopy with 10-year followup. *Clin Orthop Relat Res* 2010;468(3):741-746.
4. Foulk DM, Mullis BH: Hip dislocation: Evaluation and management. *J Am Acad Orthop Surg* 2010;18(4):199-209.
5. Harris JD, McCormick FM, Abrams GD, et al: Complications and reoperations during and after hip arthroscopy: A systematic review of 92 studies and more than 6,000 patients. *Arthroscopy* 2013;29(3):589-595.
6. Park MS, Her IS, Cho HM, Chung YY: Internal fixation of femoral head fractures (Pipkin I) using hip arthroscopy. *Knee Surg Sports Traumatol Arthrosc* 2014;22(4):898-901.
7. Ganz R, Gill TJ, Gautier E, Ganz K, Krügel N, Berlemann U: Surgical dislocation of the adult hip a technique with full access to the femoral head and acetabulum without the risk of avascular necrosis. *J Bone Joint Surg Br* 2001;83(8):1119-1124.
8. Swiontkowski MF, Thorpe M, Seiler JG, Hansen ST: Operative management of displaced femoral head fractures: Case-matched comparison of anterior versus posterior approaches for Pipkin I and Pipkin II fractures. *J Orthop Trauma* 1992;6(4):437-442.
9. Svoboda SJ, Williams DM, Murphy KP: Hip arthroscopy for osteochondral loose body removal after a posterior hip dislocation. *Arthroscopy* 2003;19(7):777-781.
10. Guadilla J, Fiz N, Andia I, Sánchez M: Arthroscopic management and platelet-rich plasma therapy for avascular necrosis of the hip. *Knee Surg Sports Traumatol Arthrosc* 2012;20(2):393-398.
11. Ong C, Hall M, Youm T: Surgical technique: Arthroscopic treatment of heterotopic ossification of the hip after prior hip arthroscopy. *Clin Orthop Relat Res* 2013;471(4):1277-1282.
12. Bedi A, Zbeda RM, Bueno VF, Downie B, Dolan M, Kelly BT: The incidence of heterotopic ossification after hip arthroscopy. *Am J Sports Med* 2012;40(4):854-863.
13. Davidovitch RI, Alaia MJ, Patel D, et al: The incidence of venous thromboembolism (VTE) after hip arthroscopy. *Arthroscopy* 2012;28(6):e24-e25.
14. Bartlett CS, DiFelice GS, Buly RL, Quinn TJ, Green DS, Helfet DL: Cardiac arrest as a result of intraabdominal extravasation of fluid during arthroscopic removal of a loose body from the hip joint of a patient with an acetabular fracture. *J Orthop Trauma* 1998;12(4):294-299.
15. Epstein HC, Wiss DA, Cozen L: Posterior fracture dislocation of the hip with fractures of the femoral head. *Clin Orthop Relat Res* 1985;201:9-17.
16. Philippon MJ, Kuppersmith DA, Wolff AB, Briggs KK: Arthroscopic findings following traumatic hip dislocation in 14 professional athletes. *Arthroscopy* 2009;25(2):169-174.
17. Ilizaliturri VM Jr, Gonzalez-Gutierrez B, Gonzalez-Ugalde H, Camacho-Galindo J: Hip arthroscopy after traumatic hip dislocation. *Am J Sports Med* 2011;39(1 suppl):50S-57S.
18. Matsuda DK, Safran MR: Arthroscopic internal fixation of osteochondritis dissecans of the femoral head. *Orthopedics* 2013;36(5):e683-e686.
19. Zalavras CG, Lieberman JR: Osteonecrosis of the femoral head: Evaluation and treatment. *J Am Acad Orthop Surg* 2014;22(7):455-464.
20. Rao J, Zhou YX, Villar RN: Injury to the ligamentum teres: Mechanism, findings, and results of treatment. *Clin Sports Med* 2001;20(4):791-799, vii.
21. de SA D, Phillips M, Philippon MJ, Letkemann S, Simunovic N, Ayeni OR: Ligamentum teres injuries of the hip: A systematic review examining surgical indications, treatment options, and outcomes. *Arthroscopy* 2014;30(12):1634-1641.
22. Hougaard K, Thomsen PB: Traumatic posterior dislocation of the hip: Prognostic factors influencing the incidence of avascular necrosis of the femoral head. *Arch Orthop Trauma Surg* 1986;106(1):32-35.
23. Brav EA: Traumatic dislocation of the hip: Army experience and results over a twelve-year period. *J Bone Joint Surg Am* 1962;44:1115-1134.
24. Park MS, Yoon SJ, Choi SM: Hip arthroscopic management for femoral head fractures and posterior acetabular wall fractures (Pipkin Type IV). *Arthrosc Tech* 2013;2(3):e221-e225.
25. Lansford T, Munns SW: Arthroscopic treatment of Pipkin type I femoral head fractures: A report of 2 cases. *J Orthop Trauma* 2012;26(7):e94-e96.
26. Yamamoto Y, Ide T, Ono T, Hamada Y: Usefulness of arthroscopic surgery in hip trauma cases. *Arthroscopy* 2003;19(3):269-273.
27. Khanna V, Harris A, Farrokhyar F, Choudur HN, Wong IH: Hip arthroscopy: Prevalence of intra-articular pathologic findings after traumatic injury of the hip. *Arthroscopy* 2014;30(3):299-304.
28. Mullis BH, Dahners LE: Hip arthroscopy to remove loose bodies after traumatic dislocation. *J Orthop Trauma* 2006;20(1):22-26.
29. McCarthy J, Puri L, Barsoum W, Lee JA, Laker M, Cooke P: Articular cartilage changes in avascular necrosis: An arthroscopic evaluation. *Clin Orthop Relat Res* 2003;406:64-70.

30. Evans CH, Mazzocchi RA, Nelson DD, Rubash HE: Experimental arthritis induced by intraarticular injection of allogenic cartilaginous particles into rabbit knees. *Arthritis Rheum* 1984;27(2): 200-207.
31. Keene GS, Villar RN: Arthroscopic loose body retrieval following traumatic hip dislocation. *Injury* 1994;25(8): 507-510.
32. Larson CM, Guanche CA, Kelly BT, Clohisy JC, Ranawat AS: Advanced techniques in hip arthroscopy. *Instr Course Lect* 2009;58:423-436.
33. Byrd JW, Jones KS: Primary repair of the acetabular labrum: Outcomes with 2 years' follow-up. *Arthroscopy* 2014;30(5): 588-592.
34. Mont MA, Zywiell MG, Marker DR, McGrath MS, Delanois RE: The natural history of untreated asymptomatic osteonecrosis of the femoral head: A systematic literature review. *J Bone Joint Surg Am* 2010;92(12):2165-2170.
35. Beck DM, Park BK, Youm T, Wolfson TS: Arthroscopic treatment of labral tears and concurrent avascular necrosis of the femoral head in young adults. *Arthrosc Tech* 2013;2(4):e367-e371.
36. Gupta AK, Frank RM, Harris JD, McCormick F, Mather RC, Nho SJ: Arthroscopic-assisted core decompression for osteonecrosis of the femoral head. *Arthrosc Tech* 2014;3(1):e7-e11.
37. Ellenrieder M, Tischer T, Kreuz PC, Fröhlich S, Fritsche A, Mittelmeier W: Arthroscopically assisted therapy of avascular necrosis of the femoral head [German]. *Oper Orthop Traumatol* 2013;25(1):85-94.
38. Zhuo N, Wan Y, Lu X, Zhang Z, Tan M, Chen G: Comprehensive management of early stage avascular necrosis of femoral head by arthroscopic minimally invasive surgery [Chinese]. *Zhongguo Xiu Fu Chong Jian Wai Ke Za Zhi* 2012;26(9): 1041-1044.